

+ Evidence in focus

Publication summary: Farivar BS, et al. *J Vasc Surg Venous Lymphat Disord* (2019)*

Smith+Nephew

Addition of GRAFIX[◇] Cryopreserved Placental Membrane to standard therapy increased wound healing in patients with non-healing venous leg ulcers (VLUs)

+ Plus points



Complete wound closure for 53% of non-healing VLUs after adding GRAFIX Membrane to standard therapy



63%
Significantly **greater relative decrease** in VLU surface area from adding GRAFIX Membrane to standard therapy (79.2 vs 29.2%; $p < 0.001$)

80%

Of VLUs had a **≥50% wound area reduction in 12 weeks** (vs 25% for standard therapy; $p < 0.001$)

Overview

- Prospective, open-label, self-controlled, single-arm cohort study
- Patients (N=21; all males; ankle brachial index < 0.8) with 30 VLUs that had failed to respond to 12 weeks of standard therapy with wound cleansing, surgical debridement and multilayer compression therapy (observational control period)
 - Mean wound area was 12.2cm²
- Patients received GRAFIX Membrane a maximum of 12 times during the 12 weeks of the study (crossover treatment period)
 - Patients continued to receive standard therapy

Results

- Addition of GRAFIX Membrane to standard therapy resulted in complete wound closure for 53% of VLUs within 10.9 weeks (primary endpoint)
 - No VLUs recurred during the study
- Wound surface area was significantly reduced with GRAFIX Membrane added to ongoing standard therapy compared with prior standard therapy ($p < 0.001$; Figure)
- Addition of GRAFIX Membrane to ongoing standard therapy significantly increased the number of VLUs with $\geq 50\%$ area reduction versus prior standard therapy (80 vs 25%; $p < 0.001$)
- Mean number of GRAFIX Membrane applications was 7.2

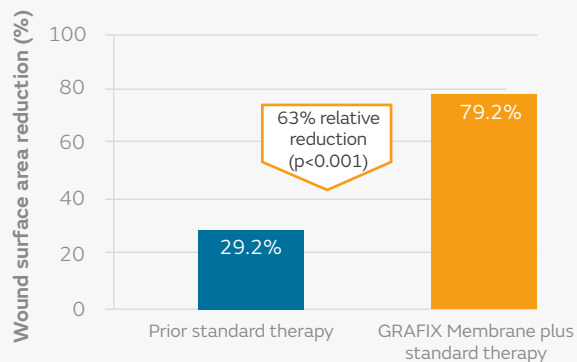


Figure. Wound surface area reduction with 12 weeks prior standard therapy and following addition of GRAFIX Membrane to ongoing standard therapy for the next 12 weeks

Conclusions

Addition of GRAFIX Membrane to standard therapy helped to achieve complete wound closure and to reduce wound area compared with prior standard therapy in patients with non-healing VLUs.

Citation

*Farivar BS, Toursavadkahi S, Monahan TS, et al. Prospective study of cryopreserved placental tissue wound matrix in the management of chronic venous leg ulcers. *J Vasc Surg Venous Lymphat Disord*. 2019;7(2):228–233.

Available from: [Journal of Vascular Surgery: Venous and Lymphatic Disorders](#)

For detailed product information, including indications for use, contraindications, precautions and warnings, please consult the product's applicable Instructions for Use (IFU) prior to use.